

ENSURING SAFETY FOR INFANTS UNDERGOING MAGNETIC RESONANCE IMAGING

LAURA A. STOKOWSKI, RN, MS

ABSTRACT

Magnetic resonance imaging (MRI) is a powerful and versatile diagnostic tool. Applications of MR technology are rapidly expanding for all patient populations, including infants receiving newborn intensive care. Millions of MR examinations have been conducted without incident or harm, yet rare accidents in the MR environment continue to occur. The infant is vulnerable to many of the potential hazards of MRI, including projectile accidents, radiofrequency electromagnetic field effects, noise hazards, physiologic instability, and adverse effects of transport, positioning, handling, and sedation. The MRI-compatible incubator is a promising means for safe imaging of smaller and less stable infants than previously possible. Proper education of staff and meticulous attention to detail in preparing the infants for MR examinations are the keys to safety during neonatal MRI.

KEY WORDS: infant, magnetic resonance imaging (MRI), safety, hazards, accidents.

One look at a typical magnetic resonance imaging (MRI) scanner is all it takes to know that it was not designed for an infant.¹ MRI scanners are large, noisy, and often situated in remote locations relative to the neonatal intensive care unit (NICU). When the first adult patient was scanned in 1977,² perhaps no one envisioned that despite these obstacles it would not be long before the smallest and most fragile of patients would be sliding into the scanner to take advantage of this remarkable new technology.

Infants now routinely undergo MRI of the head, chest, abdomen, spine, and pelvis for a multitude of diagnostic purposes. Although cranial ultrasonography remains the imaging modality of choice for early sequential scans to detect intracranial hemorrhage,³ MRI techniques are superior for most other diagnostic and prognostic neuroimaging applications (Table 1).⁴⁻⁶

Magnetic resonance imaging, as currently practiced, is considered biologically harmless.⁷ In fact, compared

to many other diagnostic procedures, MRI is among the most powerful, yet safest procedures created in the history of modern medicine.⁸ For a complete definition of technical terms related to MRI see Table 2.^{9,10}

Unlike x-rays or computed tomography (CT) scans, MRI does not use ionizing radiation. Instead, MRI uses an extremely powerful static magnetic field, rapidly changing gradient magnetic fields, and radiofrequency electromagnetic impulses to produce detailed anatomic or functional images of the brain and other soft tissues of the body. For a detailed description of how MRI images are acquired and constructed see Sidebar 1.^{11,12} No short- or long-term adverse effects from MRI at field strengths and durations clinically used to date have been identified.¹³

Despite its relative safety, there are potential hazards associated with MRI. Some are related to the physical properties of the MR equipment and others to the challenges of maintaining physiologic stability of the infant undergoing the examination in a location remote from the NICU. This article addresses these potential hazards and provides strategies to promote safety for infants undergoing MRI, specifically focusing on hospitalized infants requiring newborn intensive care. The article does not address issues specific to older infants receiving MRIs in the outpatient setting.

MAGNETIC FIELDS AND THE MISSILE EFFECT

A small boy undergoing an MRI following surgery to remove a benign brain tumor was struck and killed by an oxygen tank inadvertently taken into the

Address reprint requests to Laura A. Stokowski, RN, MS, Inova Fairfax Hospital for Children, Neonatal Intensive Care Unit, 3300 Gallows Road, Falls Church, VA 22042-3300. E-mail: stokowski@cox.net

From the Inova Fairfax Hospital for Children, Falls Church, Va.

No conflicts of interest disclosed.

Copyright © 2005 by The National Association of Neonatal Nurses
1536-0903/05/0501-0006\$30.00/0
doi:10.1016/j.adnc.2004.07.006

Table 1. Comparing and Contrasting Neuroimaging Tests in Infants⁴⁻⁶

Neuroimaging Options	Primary Uses	Advantages	Disadvantages
Cranial Ultrasound	<ol style="list-style-type: none"> 1. Screen for IVH in high-risk premature infants 2. Monitor progression of GMH, IVH, PVL, ventriculomegaly 3. Define cerebral anatomy 4. Assess cerebral blood flow velocity 	<ul style="list-style-type: none"> • Mobile, portable • Can be performed at any time; amenable to serial studies • Bedside testing completed with minimal infant disturbance • Full intensive care continues during examination • Safe, harmless; no ionizing radiation 	<ul style="list-style-type: none"> • Limited accuracy in defining HIE, arterial infarcts • Findings do not always correlate well with neurodevelopmental outcomes
Computed Tomography (CT)	<ol style="list-style-type: none"> 1. Detect intracranial hemorrhage in infants with history of acute encephalopathy, significant birth trauma, and evidence of low hematocrit or coagulopathy 2. Detect basal ganglia/thalamic lesions 3. Detect calcifications 	<ul style="list-style-type: none"> • Often preferred over ultrasound in full-term infants at low risk for IVH and higher risk for other cranial processes • Examination is quick • Sedation not required • Monitoring of patient possible during examination 	<ul style="list-style-type: none"> • Timing of the test impacts accuracy in detecting specific lesions • Exposure to ionizing radiation • Involves transport to radiology department
Magnetic Resonance Imaging (MRI)	<ol style="list-style-type: none"> 1. Determine cause of early neonatal seizures, with or without signs of birth asphyxia 2. Detect neonatal cerebral arterial infarction (stroke) 3. Define pattern of tissue injury in neonatal encephalopathy 4. Diagnose cerebellar malformations, superior ability to visualize the posterior fossa 5. Diagnose CNS manifestations of metabolic disorders 	<ul style="list-style-type: none"> • Unparalleled sensitivity to changes in gray and white matter and ability to differentiate myelinated from unmyelinated white matter • Does not use ionizing radiation; biologically harmless at current field strengths • Excellent predictive value for outcomes related to neonatal encephalopathy⁶ • Even more promising techniques on the horizon 	<ul style="list-style-type: none"> • Timing of the test impacts accuracy in detecting specific lesions • Must transport infant to radiology department; challenge to continue provision of intensive care • Difficult to monitor infant during examination • Noisy • Safety issues related to static magnetic field • May require sedation of infant; sensitive to movement

Abbreviations: CNS, central nervous system; GMH, germinal matrix hemorrhage; IVH, intraventricular hemorrhage; PVL, periventricular leukomalacia; HIE, hypoxic-ischemic encephalopathy.

MRI suite. The metal tank, about the size of a fire extinguisher, became a magnet-seeking missile when brought within reach of the 10-ton magnet's field. Pulled through the air by magnetic force into the bore of the MRI system, the oxygen tank attached itself to the magnet, simultaneously fracturing the immobilized child's skull and causing a fatal cerebral hemorrhage.¹⁴

This tragic scenario illustrates the greatest threat to patient safety associated with MRI: the static magnetic field generated by a powerful magnet. Tens of thousands times stronger than the earth's magnetic field, the MR system's magnet can attract objects containing ferrous materials, transforming them into dangerous airborne projectiles.¹⁵ The ability of the magnet to

attract a ferromagnetic object and draw it rapidly into the bore with considerable force is referred to as the *missile effect*.¹⁰ Ferromagnetic objects are metallic items containing iron, such as scissors, laryngoscopes, nail clippers, pocket knives, and steel buckets. Even very large items, such as wheelchairs, gurneys, IV poles, and floor buffering machines, have become unintended MR-system-induced missiles¹⁰ (Fig 1).

MAGNETIC FIELD INTERACTIONS

The static magnetic field of an MR system is always on. No sound, sight, or smell alerts personnel to the presence or the extent of the invisible field sur-

Table 2. Magnetic Resonance Imaging Definition of Terms^{9,10}

Diffusion-weighted imaging (DWI)	An imaging technique that analyzes the molecular motion of water in tissues such as the brain. Clinical applications include assessment of white matter pathology in preterm infants and term infants with neonatal encephalopathy.
Ferromagnetic	A substance, such as iron, that has a large, positive, magnetic susceptibility (ability to become magnetized when placed within a magnetic field).
5-Gauss line	Perimeter around an MR system within which the static magnetic fields are higher than 5 gauss. Five gauss and below are considered “safe” levels of static magnetic field exposure for the general public.
Flux	Invisible lines of force that extend around a magnetic material.
Fringe field	The region surrounding a magnet and exhibiting a magnetic field strength that is significantly higher than the earth’s magnetic field. The size of the fringe field depends on the magnet type and field strength. The higher the field strength, the larger the fringe field. Fringe field is also called the <i>stray field</i> .
Gauss (G)	A unit of magnetic flux density. Gauss is 1 of 2 units used to measure magnetic field strength; the other and current preferred (SI) unit is the Tesla (10,000 Gauss = 1 Tesla).
Gradient magnetic fields	A magnetic field that changes in strength in a certain direction. Gradient magnetic fields are used in MR imaging with selective excitation to select a region for imaging and also to encode the location of MR signals received from area being imaged.
Magnetic resonance	Phenomenon resulting in the absorption and/or emission of electromagnetic energy by nuclei or electrons in a static magnetic field, after excitation by a radiofrequency magnetic field.
Magnetic resonance angiography (MRA)	Imaging of the flow of blood in the arteries and veins of the body. Clinical applications in infants include evaluation of arteriovenous malformations, vascular accidents (strokes), and assessment of carotid artery blood flow following extracorporeal membrane oxygenation (ECMO) therapy.
Magnetic resonance spectroscopy (MRS)	Utilizes the principle that nuclei in different chemical structures have different characteristic resonance patterns, or spectra. MRS is used to study brain biochemistry and metabolism. Clinical applications in the newborn include hypoxic-ischemic encephalopathy and inborn errors of metabolism. Often performed in conjunction with MRI.
Missile effect	Occurs when a ferromagnetic object rapidly and forcefully accelerates into the bore of a magnet. Also called the projectile effect.
MR-safe	The device, when used in the MR environment, has been demonstrated to present no additional risk to the patient, but may affect the quality of the diagnostic information.
MR-compatible	The device, when used in the MR environment, is MR safe and has been demonstrated to neither significantly affect the quality of the diagnostic information nor have its operations affected by the MR system.
Radiofrequency electromagnetic energy	Electromagnetic waves with a frequency band in the electromagnetic spectrum, or the same general range as that used for transmission of radio and television signals.
Radiofrequency pulse	Burst of RF energy delivered by the RF transmitter. These low-frequency pulses generate the signal that is measured during each scan. They also generate the heat associated with MRI (estimated by the specific absorption rate or SAR).
Room shielding	Magnetic shielding with high permeability in the walls, floor, and ceiling of the magnet room; can be complete or partial depending on the need to reduce the fringe field.
Rotational force	Twisting (torque) that occurs when a ferrous object attempts to align itself with the north-south orientation of the MRI magnet. Rotational force is greatest at the center of the magnetic field.
Quench	An unexpected loss of superconductivity caused by rapid increase in resistivity of the magnet. Generates heat resulting in boiling off and rapid evaporation of cryogen (liquid helium). Can cause damage to the magnet and anoxic conditions in the atmosphere of the magnet room if not properly vented.

Table 2. Magnetic Resonance Imaging Definition of Terms^{9,10} (Cont'd)

Specific absorption rate (SAR)	Energy deposited in tissues in the form of heat from the use of rapidly changing electromagnetic fields. The SAR is the amount of energy dissipated in the tissues, in watts per kg of tissue mass. Inhomogeneity of the RF field can lead to a local exposure where most of the power is absorbed by one body region. SAR limits (averages) are established by the FDA, usually per unit of time.
Static magnetic field	A component of the MR environment that is always present, even when the scanner is not imaging. This static magnetic field is typically between 0.2 and 2.0 tesla (T) measured in the center of the magnet bore. A 1.0 T magnet's static magnetic field would be roughly 20,000 times stronger than the earth's magnetic field.
Superconducting magnet	A type of magnet that has no electrical resistance when operated at temperatures near absolute zero.
Tesla	The preferred (standard international or SI) unit of magnetic flux density.
Time-varying magnetic fields (TVMFs)	Also called <i>gradients</i> , these are magnetic field changes introduced to spatially encode the MR signal during a scan. TVMFs can induce currents in conductive material lying within the rapidly changing magnetic field, such as muscles, nerves, and blood vessels of the human body, which are all conductive materials. TVMFs are also the source of loud noises within the scanner.
Translational force	The attraction that acts to draw an object linearly into the center of the magnet; it is the force that causes the projectile or missile effect.

rounding the magnet in all directions. The magnetic pull is strongest at the center of the MR-system magnet, and it weakens with increased distance from the magnet, creating a spatial magnetic field gradient. The distribution of the magnetic field outside of the main magnet (also called the *fringe field*) is impossible to see, but it is critical to safety in the MR environment because it can determine whether a ferromagnetic object could become a projectile.

The risk of such an event depends on features of each facility's MR system and its environment. These include the main magnet strength and magnet and room shielding (Fig 2). MR systems with large fringe fields generally create the greatest hazard.⁷ Shielding can significantly reduce the magnet's fringe field; therefore, newer MR systems integrate such shielding into their designs. The fact that an MR system's magnet is shielded, does not mean it is safe to bring ferrous objects or equipment into the magnet's vicinity.

There are 2 ways a ferromagnetic object can react to the magnetic field. One is translational force; the other is rotational force. Translational force is operating when an object is strongly pulled to the center of the magnetic field, as is the case with an airborne projectile. Rotational force (also known as *torque*) occurs when an object within the magnetic field tries to align itself with the magnet. Torque can cause a stationary ferromagnetic object, even one within a person's body, to twist and rotate in position.

When there is a high spatial gradient (e.g. the magnetic field drops off rapidly at a short distance from the magnet portal), a ferromagnetic object can appear to be unaffected by the magnetic field until it approaches the magnet, at which point it can suddenly

become forcefully and rapidly attracted to the magnet. If the fringe field strength decreases more gradually with distance from the magnet (a low spatial gradient), the object's attraction to the magnet progressively strengthens as it becomes closer to the magnet. In some ways, a lower spatial gradient might be safer. Personnel within the MR room may notice an increasingly stronger pull on objects they are wearing or carrying as they walk closer to the MR system, permitting them to retreat from the MR system magnet before an accident occurs.¹⁶ Table 3 provides a cogent summary of hazardous magnetic field interactions.

STATIC MAGNETIC FIELD SAFETY

A safety boundary, the *5-Gauss line*, can be demarcated and controlled to help prevent static-magnetic-field-related accidents from occurring.⁷ At 5-Gauss (0.0005 Tesla, or 0.5 mT) the magnetic pull is so low that ferrous objects will not become magnetized. The position of the 5-Gauss boundary line relative to the MR system will vary depending on the strength of the main magnet.⁷ Ideally, the 5-Gauss line is the minimum perimeter around the MR system beyond which all non-MRI safe equipment and unscreened individuals, particularly those with pacemakers, should remain. In reality, however, the 5-Gauss line can be quite far from the MR system and might even be located outside of the MR room. In these facilities, a 10- or 20-Gauss line might be used within the MR room for safety purposes.

With so many variables affecting the size of the static and fringe fields, it is crucial that staff accompanying infants to MRI are aware of the factors operating in their own facility. Nurses working in more than 1 hospital need

SIDEBAR 1. HOW DOES A MAGNET CREATE AN IMAGE?

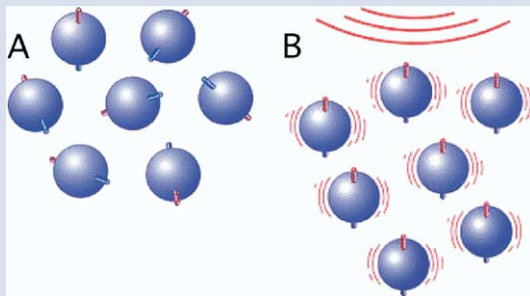
A basic understanding of the process of MR image acquisition will help caregivers take safe actions and avoid unsafe ones, when caring for infants undergoing MRI. When the infant is placed in the bore of the scanner, 2 things happen to the hydrogen atoms that comprise the fat and water of the body's tissues. The usually randomly oriented protons (A) contained in the nuclei of the hydrogen molecules become uniformly aligned either parallel or antiparallel to the powerful magnet field (B). In addition, the protons, which normally spin on their axes much like the earth spins on its axis, start spinning around the direction of the external magnetic field.¹¹

Next, the coils surrounding the infant's head or torso deliver short bursts of electromagnetic waves called radiofrequency (RF) pulses. This energy is absorbed by the protons, causing them to resonate. The applied energy deflects the protons off their alignment with the magnetic field and causes them all to briefly spin in phase with one another.¹¹

When the RF pulse is off, the superenergized protons recover their alignment and out-of-phase spin, a process called relaxation.¹¹ During relaxation, protons release the stored energy, emitting detectable RF signals. Relaxation behavior is strongly dependent on the tissue type in which the nucleus is located (e.g. gray matter, white matter, cerebrospinal fluid). These differences in relaxation times are the source of tissue contrast in the MR image.²

The signals that are returned do not have spatial information, so 3 magnetic field gradients are switched on and off with the RF pulses. Known as time varying magnetic field gradients, these are brief, low-strength currents applied to provide unique magnetic fields that help to localize signals to the region of interest. This encoding process allows control of the location and thickness of the slice of tissues that will be excited by magnetic resonance.¹²

The signals transmitted from the infant are transferred via the receiving coils to a computer, where they are translated into detailed 2- or 3-dimensional anatomic images of the tissues of interest. A great deal of data is obtained to generate the final MR image. The more data points collected, the more detailed the final image.¹¹



Randomly oriented spinning protons (A) aligning within a magnetic field (B) at the start of the MRI process. *BMJ*. 2002;324:35. Used with permission from the BMJ Publishing Group.

to be familiar with MRI configurations at each facility. Accidents and near misses usually occur when non-MRI personnel who are unfamiliar with MRI routines accompany a patient to the MRI suite.¹⁷ These individuals might not be aware of the invisible, yet very real hazards to patients and to themselves. Before entering the scanning room, NICU staff accompanying an infant to the MRI suite must comply with all safety procedures, including systematic screening, mandated by MRI staff¹⁷ (Fig 3). Some MRI departments use large hand-held magnets to screen staff members and patients before they are permitted to enter the MRI suite.

MR SAFE VERSUS MR COMPATIBLE

The field of MRI is growing rapidly. As the number of MR techniques increases, so will the number of biomedical implants, products, and devices carrying labels such as *MRI safe* or *MRI compatible*. Everyone involved in MR studies needs to understand what this labeling means.

The terms *MR safe* and *MR compatible* are not interchangeable.¹⁸ *MR safe* means that the product or device does not contain any ferromagnetic material and will not become magnetized in the vicinity of the MR system, but there is no guarantee that it will operate properly in proximity to the magnet. *MR compatible* denotes a piece of equipment that is both *MR safe* and can be used in the MR environment without significant effect on its operation or the quality of its diagnostic information.⁹ Manufacturers should also report the conditions under which the product or device was tested for safety or compatibility so that end-users can determine if they are appropriate to their respective MR environments.¹⁸

Some equipment also carries labeling that it is *MR safe* or *MR compatible* "if secured to a non-moveable object," or as long as it is kept a minimum distance from the magnet.¹⁹ Because it is impossible to predict how such an item will react in the presence of different MR scanners or at different locations in a room, the safest location for this equipment must be determined by MR-trained staff. No one should subsequently move this equipment to bring it closer to the patient. Longer cables or tubing, as appropriate, should be used instead.

Never assume that objects or equipment found in or around the MR system room are *MR safe* or *compatible* unless these objects are clearly labeled as such.⁸ The American College of Radiology also recommends that portable metallic or partially metallic objects stored in or near the magnet room be labeled "Not MR Safe."⁸

To make equipment *MR safe*, manufacturers can substitute copper, brass, or aluminum for the major ferrous components.²⁰ However, these materials are still electrical conductors and, as such, pose a hazard in the MR environment. Some machines have internal delicate instrumentation that is ferromagnetic. This instrumentation can be damaged by torque as the magnet exerts rotational or alignment effects on the ferromagnetic

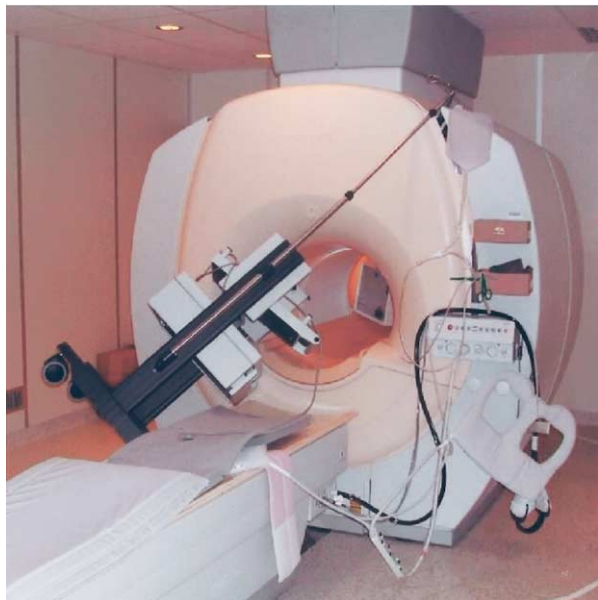


Figure 1. Wheeled IV pole with infusion pumps flew into the bore of this magnet. If there had been a patient on the scanning table, the patient could have been severely injured. Image used with permission of Moriel Ness Aiver, PhD, www.simplyphysics.com.

parts.²⁰ These devices might not be projectile hazards in the MR room, but their operation will nonetheless be affected.

Equipment that does not operate properly in the magnet room is more than an inconvenience—it can be a serious safety hazard on many different levels. Because the magnet discharges batteries, battery-powered devices (laryngoscopes, microinfusion pumps, monitors, etc.) can suddenly fail to operate at a critical moment. Physiologic monitoring is essential during the examination because it is almost impossible to visualize the infant within the bore of the MR system.²¹ If the monitoring equipment is not MR compatible, the data needed to continuously assess the infant's condition during the examination might be lost, creating a potentially dangerous situation. Accordingly, use only equipment tested and approved for use during MRI in this setting.¹⁶

Every NICU should develop an institution-specific reference that lists MRI-safe and MRI-compatible equipment and devices to assist staff who are preparing to transport an infant to the MRI suite. This list must include items that are semipermanently attached to the infant, such as endotracheal tube stabilization devices, umbilical cord clamps, infant security devices, identification bands, indwelling tubes and catheters, and any other items that may appear in the infant's microenvironment. Although it is important to remove unsafe items before MRI, it is also important to avoid unnecessary removal of other items.

RADIOFREQUENCY ELECTROMAGNETIC FIELD EFFECTS

Within the MR system are electromagnetic coils and a transmitter that delivers the radiofrequency (RF) pulses during imaging. When tissues absorb the RF energy, tissue heating can occur, particularly in patients with poor thermoregulatory control.¹⁵ Preterm infants and other sick infants fit into this category; however, specific studies of body temperature homeostasis during MRI in this population are lacking. The rate at which RF energy is deposited in tissue is defined as the *specific absorption rate* (SAR), which is measured in units of watts per kilogram (W/kg).¹⁰ The maximum allowable SAR is 3 W/kg (averaged over 10 minutes) for head imaging and 4 W/kg (averaged over 15 minutes) for whole body imaging.²² It is critical to provide the MR technologist with the infant's actual body weight to avoid excessive RF exposure.

Radiofrequency fields can cause skin burns if monitor cables or wires are permitted to form conductive loops with themselves or with parts of the body.⁸ Although rare, skin burns have been reported in association with pulse oximeter sensors and cardiorespiratory monitor cables in patients who require monitoring during MRI.¹¹ Temporary metallic intracardiac pacing wires will behave like antennae and conduct electromagnetic waves, also resulting in thermal tissue injury.²³

Thermal injuries associated with electrocardiogram (ECG) monitoring can be virtually eliminated by using fiberoptic MR-compatible cables and pulse oximetry cables.¹⁸ Use only MR-compatible ECG and pulse oximetry accessories; remove chest leads and pulse oximetry sensors used during transport and replace with MR-compatible substitutes. Place electrodes close together but not touching, and braid leads so that the wires do not form conductive loops.²⁴ Rest wires along the long axis of the infant's body, avoiding skin contact.

A concentration of electrical current sufficient to cause excessive heating and burns can occur if items with the potential to conduct electricity are placed within the RF field.¹⁶ Inspect the infant, blankets, and clothing for electrically conductive items before imaging begins.⁷ It is easy to overlook a safety pin attached to an armboard or tape flag, or a metal clamp on a gastrostomy tube. Check umbilical or limb security devices and name bands with metal parts for MR safety before entering the MRI suite; remove them if deemed unsafe.¹⁷ Apply MR-safe identification bands for the procedures; these can be replaced with standard security devices after the MRI is completed. Conventional temperature probes used for servo-controlled incubators and radiant warmers are not safe for use during MRI and must be removed.

Radiofrequency signals emitted during the MR examination can affect non-MR-compatible programmable infusion pumps, resulting in erratic performance.



Figure 2. The superconducting magnet is an electromagnet in which current flowing in a circular direction in a coil of wire produces the intense, homogenous magnetic field required for high-quality imaging. Most MR magnets in hospitals are 1.5 Tesla or lower in strength; those used for research in infants can be up to 4 Tesla in strength. Image used with permission of Stephen Brick, MD, www.gcmradiology.com.

Without warning, affected pumps could deliver higher or lower than desired volumes of pressor agents, analgesics, sedatives, or dextrose and electrolyte solutions—all of which could have serious physiologic consequences for the infant. Secure an essential infusion pump well outside of the fringe field of the magnet using enough extension tubing to reach the scanning table.²⁵

Radiofrequency interference can work both ways. Electronic equipment in the area can interfere with the RF transmission and reception in the magnetic field.¹⁵ Such interference can be reduced with shielding. Usually, a copper RF shield, preventing the high-power RF pulses from radiating out through the hospital, surrounds the imaging room itself. Shielding prevents external RF signals from television and radio stations from being detected by and interfering with the MR imager.¹⁵

GRADIENT MAGNETIC FIELD EFFECTS

Subjecting the infant to sudden, rapidly changing gradient magnetic fields during imaging can induce circulating currents in conductive tissues of the body.²⁶ In theory, these currents are large enough to produce changes in nerve and muscle function, such as peripheral nerve stimulation or pain. In extreme cases, cardiac stimulation could occur. Safety standards limit the maximum rates of change of magnetic field strength that can be used, so these effects are not likely to be observed during routine clinical MRI.¹⁰

ACOUSTIC NOISE HAZARD

Inside the bore of the MR system, the imaging process can be extremely loud. The chief source of noise is the gradient magnetic field.¹⁵ The rapidly shifting current causes the gradient magnetic coils to flex and vibrate against their moorings, producing loud clunking and knocking sounds.²⁷ Noise levels vary, depending on the particular pulse sequences used and the strength of the magnetic field.²⁷ Noise levels up to 93 dB (A) are typical during an MR examination, and peak levels can even reach 110 dB (A) during some sequences.²⁷ Maximum allowable sound pressure level during MRI is 140 dB (unweighted) or 99 dB (A) with hearing protection in place.²³

Significant MRI-induced noise can produce hearing loss in patients who are susceptible to the damaging effects of loud noises.²⁷ Infants may have multiple risk factors for hearing loss and must be protected from additional noise exposure. Use of disposable earplugs, which can reduce noise levels by 10 to 30 dB when properly applied, is mandatory during MRI.²⁷ In addition to ear plugs, commercially available ear muffs are recommended for added hearing protection. Vacuum fixation pillows used to position and stabilize infants during imaging provide additional sound attenuation.²¹

BIOMEDICAL IMPLANT HAZARDS

A significant risk to some patients undergoing MRI is the way implanted or internal ferromagnetic material can react to the strong magnetic field and RF impulses. When implanted ferromagnetic material, such as a metallic aneurysm clip, is exposed to the magnetic field, it can be subjected to torque and translational forces strong enough to tear surrounding tissues.¹⁵ MR compatibility of these devices must be demonstrated by manufacturer's declaration (including conditions under which testing was conducted) or Food and Drug Administration (FDA) clearance.¹⁵ A list of biomedical implants and compatibility information is available online at www.MRIsafety.com.

The metallic cardiac occluders used in infants for patent ductus arteriosus ligation or ventricular septal defect occlusion can be made of weakly ferromagnetic material. They are considered safe 6 to 8 weeks following surgery, when enough tissue growth has occurred to cover the occluder and keep it in place.¹⁸ Certain cochlear implants used in infants have small internal magnets that experience substantial magnetic field interactions. These magnets must be removed by a brief surgical procedure before an MRI can be conducted.¹⁷ Safety and compatibility information about biomedical implants should be prominently documented in the patient's medical record.

Staff members accompanying infants to the MRI suite are also screened for biomedical implants or metallic foreign bodies that might create a hazard in proximity to the MR magnet⁷ (Fig 3). In addition, the

Table 3. Hazardous Magnetic Field Interactions

Magnetic Field Type	Hazard	Potential Adverse Effects
Static magnetic field	<i>Translational force</i> : powerful attraction of ferromagnetic object to intense magnetic field.	<ul style="list-style-type: none"> • “Missile effect”: acceleration of object into the bore of the magnet. • Tearing of tissues, pain, dislodgement of some implants.
	<i>Rotational force/torque</i> : rotation of object to align with the magnetic field.	<ul style="list-style-type: none"> • Tearing of tissues, pain, dislodgement of some implants.
Radiofrequency electromagnetic fields	Heating due to absorbed RF energy. Electromagnetic interference.	<ul style="list-style-type: none"> • Overheating, burns (thermal, electrical). • Device malfunction; imaging artifact.
Gradient magnetic field	Induced currents in conductive tissues. Induced currents in electrical devices.	<ul style="list-style-type: none"> • Nerve and muscle stimulation. • Device malfunction/failure.

Adapted from Center for Devices and Radiological Health. A Primer on Medical Device Interactions With Magnetic Resonance Imaging Systems. U.S. Department of Health and Human Services, Food and Drug Administration, 1997.

MR system magnet can erase magnetically coded information on credit cards and passkeys and temporarily affect the function of analog watches.

RISKS TO PHYSIOLOGIC STABILITY

Although studies are few, available evidence shows that exposure to a strong static magnetic field does not threaten physiologic stability of the infant.^{28,29} Changes in vital signs during MR examinations in term and preterm infants have been documented by several studies; the cause of vital sign changes remains speculative.^{29,30} Tachycardia, bradycardia, and oxygen desaturation could be related to inadequate cardiorespiratory support during the examination.²⁸ Significant fluctuations of heart rate and blood pressure might also reflect the response of the immature autonomic nervous system to sensory stimulation during MRI.^{28,29}

Continuous physiologic monitoring is an essential safety precaution during MRI in infants.¹⁷ Monitoring devices must³¹:

- Function normally during imaging
- Not pose a danger to patients or personnel
- Not impair the quality of imaging

To fulfill these requirements, MR-compatible monitors with integrated noise filters to ensure reliable tracings during image acquisition are used. Heart rate, respiratory rate, pulse oximetry, and end-tidal carbon dioxide (EtCO₂ or capnography) are monitored continuously for all infants undergoing MRI. Respiratory impedance monitoring tends to be unreliable; instead, closely observe capnography and pulse oximetry to monitor for respiratory depression. Noninvasive blood pressure can be obtained, but inflation of the blood pressure cuff during the exam-

ination may disturb the infant and disrupt the examination. Time blood pressure assessment carefully. Position monitoring equipment so that readouts and waveforms are visible to personnel observing the infant from a distance. Once the procedure has begun, it is difficult to assess the infant visually without crawling into the bore of the magnet.²⁸ Some MR suites use a main room-dedicated monitor and a remote display monitor in the control room for continuous surveillance by NICU staff.

The NICU caregiver is responsible for monitoring the infant before, during, and after the procedure. Although facility-specific policy may dictate whether this monitoring takes place from within the MR system room or through a window in a control room, the responsible NICU staff member must be satisfied with the adequacy of monitoring display both before the procedure starts and after the procedure commences. If monitor interference or artifact is a problem during the MR examination, be direct and assertive about the need to enter the room and/or to use a plastic stethoscope to directly assess heart rate and respiration of the infant.³² If noise, monitor interference, or artifact impede the continuous assessment of the infant, or there is any doubt about the infant's stability during the scanning process, inform MR staff so that the scan can be interrupted for assessment of the infant.

Infants who require ventilation or nasal continuous positive pressure must be maintained on these modalities using either MR-compatible machines or conventional ventilators located outside of the fringe field.²⁵ In the latter circumstance, extended ventilator tubing is necessary. Adjustments in ventilator parameters may be needed to compensate for the increased dead space.²⁵ For infants who might require free-flow oxygen during scanning, nasal cannulae or oxygen tubing can be set up in advance.²¹ Although blended oxygen is

losses from the head, and consider the use of neonatal-specific, MRI-safe chemical warming packs, which can be inserted into the blankets of smaller infants who require additional thermal support.³² Take an axillary temperature before and after the examination. Dot matrix thermometers may be useful in this setting. MR-compatible temperature probes for infants are now widely available. The American College of Radiology recommends their use during neonatal MRI.³⁴

Just as it is the responsibility of NICU staff to monitor the infant, it is also their responsibility to decide when it is, or is not, appropriate to continue with an MRI examination. Intolerance of transport, adverse effects of sedation, or cold stress are examples of events that can lead to general physiologic instability. Ensuring the infant's safety might include requesting the presence of additional personnel and support, or even terminating the examination when there are valid reasons for doing so.

EMERGENCIES IN THE MR SUITE

If an infant requires anything more than minor attention during the examination, such as intubation or resuscitation, the infant must be brought out from the MR system and the magnetic fringe field for these procedures.²⁴ Unless all of the items that might be needed to conduct a resuscitation or otherwise stabilize the infant (stethoscopes, laryngoscopes, medication vials, syringes, infusion pumps, suction equipment) are MR safe, the risk of causing an accident by remaining in the MR room is too great.¹⁷ Conventional transport supply boxes and transport incubators must also be left outside of the MRI suite. In the event of a critical patient situation or code, it is imperative to evacuate the infant from the area of the MR system before other personnel arrive and perhaps carry unsafe resuscitation equipment or supplies into the room.^{8,24}

Shutting down the MR system is not quick, easy, or safe. Called a *quench*, an emergency shut down of a superconducting magnet involves boiling off the cryogenics (liquid helium) that keep the magnet cooled and in a superconducting state. Without cryogenics, the magnet loses its magnetic field. A quench can occur spontaneously due to system malfunction, or intentionally to free someone who has been pinned to the magnet by a ferromagnetic projectile. When a quench occurs, evacuate yourself and the infant from the MR system room immediately to avoid possible asphyxiation as helium replaces oxygen in the room.⁸

SAFETY AND SEDATION DURING MRI

Infant movement during an MR study causes image artifact or distortion. This can prolong the examination, perhaps causing a misdiagnosis because of

poor quality imaging. For this reason, infants often sedated during MRI studies.³⁵ Procedural sedation should be administered by anesthesia department staff or properly trained and credentialed NICU clinicians.³⁴ Sedation itself poses safety risks to infants. Those administering sedatives must carefully assess and monitor the infant and be prepared to intervene if the infant becomes compromised.³⁶ Monitoring the sedated infant and managing potential adverse events are more challenging in the MR environment than in the NICU.

Sedation can be used for both ventilated and non-ventilated infants scheduled for MRI. Agents used in infants include chloral hydrate, fentanyl, and midazolam,³⁶ a recent Cochrane Neonatal Review does question the safety of intravenous midazolam in the neonate.³⁷ In preterm infants, midazolam can also cause hypotension and a concomitant drop in middle cerebral artery blood flow velocity.³⁷

Before administering sedatives or analgesics, appropriate physiologic monitoring should be initiated, including cardiac, respiratory, pulse oximetry, noninvasive blood pressure, and end-tidal carbon dioxide monitoring for both ventilated and nonventilated patients.³⁶ Vital signs should be recorded every 5 minutes during procedural sedation of the neonate.³⁸ A sedation scoring tool, such as the Neonatal Pain, Agitation and Sedation Scale, can be used to evaluate the infant's level of sedation.³⁹

The most common side effect of sedation is respiratory depression manifested by apnea, hypoventilation, or hypoxemia.³⁸ An MR-compatible bag and mask attached to a fixed (wall) oxygen source should be available for assisted ventilation if the infant becomes apneic. Standard oxygen tanks should not be brought into the magnet room. Nonferromagnetic gas cylinders, made of aluminum, can be purchased for MR room use, but even these should be tethered to the ground to prevent accidents in the event of an erroneous cylinder exchange.⁴⁰

To avoid the dangers associated with sedation in infants, an obvious alternative is to conduct MRI examinations without sedation. Some centers report success in acquiring a neonatal MRI series without using sedation.⁴¹⁻⁴⁴ Testing is usually conducted during natural sleep immediately following a feeding, and careful attention is given to details such as noise and light reduction, sensor placement to avoid stimulation, warmth, swaddling, and positioning to minimize movement (Gary P. Zientara, PhD, personal communication, January 2004). Pacifiers are not used because they produce motion artifact. Obtaining a full MRI series in an unsedated infant usually takes more time, although administering sedation, managing adverse sedation reactions, and recovering infants from sedation are time consuming as well.

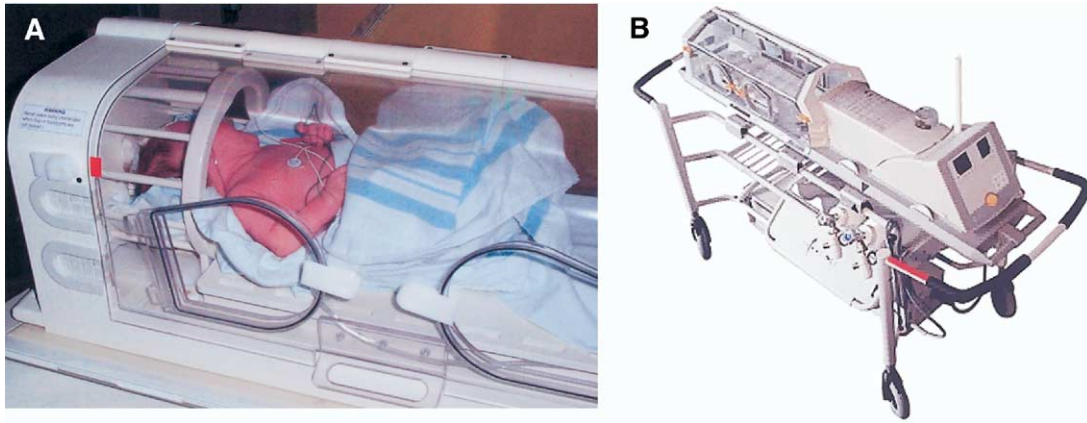


Figure 4 (A). Neonatal MR-compatible incubator with controlled temperature and humidity, and built-in radiofrequency head coil. Body coils are also available. From Bluml S, Friedlich P, Erberlich S, Woods JC, Seri I, et al. MR imaging of newborns by using an MR-compatible incubator with integrated radiofrequency coils: initial experience. *Radiology*. 2004;231:594–601. Reprinted with permission of the Radiological Society of North America. (B) Neonatal MR-compatible incubator on wheeled trolley for transporting infant within the hospital. Image used with permission of Ravi Srinivasan, PhD, Advanced Imaging Research, Inc, Cleveland, Ohio, www.advimg.com.

THE MR-COMPATIBLE INCUBATOR

Magnetic resonance imaging would be a valuable diagnostic tool for many of the smaller, sicker infants cared for in the NICU, but the difficulties of providing a safe imaging environment for these infants often preclude its use.²⁴ Dedicated scanners located within the NICU might offer a higher level of safety for MR imaging of unstable infants; however, these are rare.^{24,44}

MR-compatible incubators have recently been developed, permitting the complex and challenging task of obtaining neonatal MRI to be accomplished in a controlled microenvironment with monitoring equal to that of the NICU.^{44–48} One such incubator, custom-built to provide thermal support, complete physiologic monitoring, and blended air and oxygen in a battery-powered unit, has been successfully used to safely image infants <1 kg.⁴⁶ This unique system incorporates a camera that transmits continuous video of the infant to an external monitor throughout the scanning procedure.⁴⁵

A commercially available MR-compatible incubator (Neonate Imaging Sub-System, Advanced Research Imaging, Inc, Cleveland, Ohio) has built-in RF head coils optimized for neonatal brain volume⁴⁷ (Fig 4A, 4B). The double-wall incubator is temperature and humidity controlled and attenuates acoustic noise during scanning by 10 to 20 dB (A). The battery-powered trolley can keep the incubator functioning up to 3 hours on a single charge, and it can be plugged into a 110V AC outlet (Fig 4B). Ports on each side and a sliding patient table allow access to the infant, if necessary, without compromising the microenvironment of the incubator. Nonmagnetic air and oxygen tanks are integrated so that the infant can receive oxygen via a nasal cannula or ventilator. MR-compat-

ible monitors, infusion pumps, and a ventilator can be mounted on the incubator to create a fully mobile NICU transport incubator.

A significant advantage of the MR-compatible incubator is that once the infant is placed in the incubator in the NICU, the infant remains in a stable environment during transit to and from the radiology department and throughout the MR procedure. Upon arrival at the MRI suite, it is not necessary to retransfer the infant to the MR scanning table because the MR incubator docks directly into the bore of the magnet (Fig 5). The infant is not subjected to the cool air of the MR room or exposed to potential projectile objects.

The MR-compatible incubator appears to offer a number of safety advantages over current practices for obtaining MR studies in the infant, although the technology is quite new and experience is limited to a few centers. Anecdotal reports suggest that the use of the MR-compatible incubator controls environmental stimuli and enhances comfort; therefore, less sedation may be necessary. In many instances, the testing was completed with no sedation or anesthesia at all.⁴² The quality of imaging studies obtained using MR-compatible neonatal incubators is reported to be good to excellent.^{44,48}

Visualization of the infant within the incubator is not possible from the control room; to ensure safety, a neonatal staff member must remain in the scan room at all times.⁴⁴ Alternatively, an MR-compatible camera with a remote monitor can be added to the system to enable continuous, close-up surveillance of the infant throughout the scanning procedure.

There is a theoretical risk of overheating infants when using an external heat source (e.g., an incubator) combined with the effect of RF energy deposition

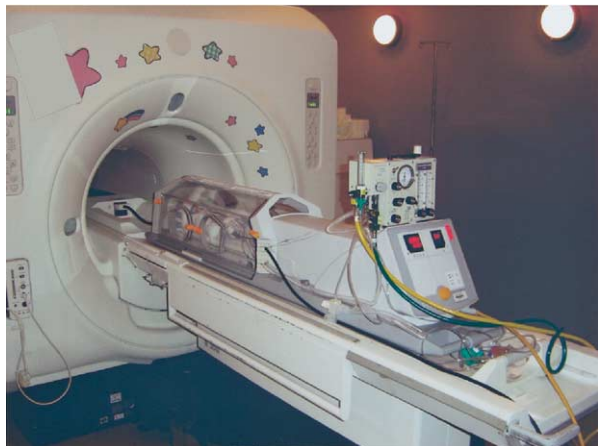


Figure 5. Neonatal MR-compatible incubator docks directly into the bore of the magnet. Image used with permission of Ravi Srinivasan, PhD, Advanced Imaging Research, Inc, Cleveland, Ohio, www.advimg.com.

during MRI.⁴⁸ This effect was monitored in a recent study that did not observe substantial increases in skin temperatures of infants within the MR-compatible incubator when RF power was applied.⁴⁸ The thermoregulatory requirements of infants during MRI is poorly understood and further study is needed to enhance clinical care.

SAFETY EDUCATION

Neonatal intensive care unit staff members who accompany infants to MRI examinations should be included in formal MRI safety training programs.⁸ A video/DVD training program, "Magnetic Resonance Imaging Safety for Non-MRI Trained Personnel" by Frank G. Shellock, PhD, a noted MRI safety expert, is available for use in formal training of hospital staff, including nurses, who might occasionally enter the MR environment (Educational Symposia, Tampa, Fla). Neonatal intensive care units should develop their own policies and procedures regarding the safe transport, care, and monitoring of infants undergoing MRI examinations that evaluating unique institutional specific hazards and that are consistent with the policies of the MR department. When there are equipment or hardware changes in the MRI suite, policies and safety training for staff should be updated accordingly.⁸

NICU and MR staff should conduct team training at regular intervals to practice handling unusual situations that pose significant threats to patient and staff safety, such as:

- Rapid removal of an unstable infant from the scanning table for resuscitation in a safe location outside of the MR room;
- A quench occurring during a MR examination.

When evaluating new products and equipment for

the NICU, consider whether or not they will be used in the MR environment and, if so, make certain they are MR safe or MR compatible, whichever is appropriate. Coordinate these decisions with the appropriate MR department personnel.

CONCLUSIONS

Magnetic resonance imaging is a relatively new technology. Dramatic improvements in technology and capabilities of this versatile modality have already taken place in the short time that MRI has been in clinical use. Ongoing research promises continuing progress and expanded applications beyond simple diagnostic studies. The potential interventional use of MRI for a variety of patient populations, including infants, is on the horizon. Fetal MRI is becoming more common, suggesting that in some instances, such as with known central nervous system anomalies, the safest and easiest time to image the infant might be before birth.⁴⁹ Safety must remain a top priority as we move forward with new clinical and research applications of MR technology for the highly vulnerable infant.

REFERENCES

1. Whitby EH, Paley MN, Smith MF, Sprigg A, Woodhouse N, et al. Low field strength magnetic resonance imaging of the neonatal brain. *Arch Dis Child Fetal Neonatal Ed.* 2003;88:F203–F208.
2. Keevil SF. Magnetic resonance imaging in medicine. *Phys Educ.* 2001;36:476–481.
3. Robertson NJ, Wyatt JS. The magnetic resonance revolution in brain imaging: impact on neonatal intensive care. *Arch Dis Child Fetal Neonatal Ed.* 2004;89:F193–F197.
4. Ment LR, Bada HS, Barnes P, Grant PE, Hirtz D, et al. Practice parameter: neuroimaging of the neonate: report of the Quality Standards Subcommittee of the American Academy of Neurology and the Practice Committee of the Child Neurology Society. *Neurology.* 2002;58:1726–1738.
5. Ambalavanan N, Nelson KG, Alexander G, Johnson SE, Biasini F, et al. Prediction of neurologic morbidity in extremely low birth weight infants. *J Perinatol.* 2000;20:496–503.
6. Rutherford MA, Pennock JM, Counsell SJ, Mercuri E, Cowan FM, et al. Abnormal magnetic resonance signal in the internal capsule predicts poor neurodevelopmental outcome in infants with hypoxic-ischemic encephalopathy. *Pediatrics.* 1998;102:323–328.
7. Price RP. The AAPM/RSNA physics tutorial for residents. MR imaging safety considerations. *Radiographics.* 1999;19:1641–1651.
8. Kanal E, Borgstede JP, Barkovich AJ, Bell C, Bradley WG, et al. American College of Radiology White Paper on MRI Safety. *AJR Am J Roentgenol.* 2002;178:1335–1347.
9. American College of Radiology. *Glossary of MR Terms.*

- 4th ed. Reston, Va: American College of Radiology; 1995.
10. Center for Devices and Radiological Health. A primer on medical device interactions with magnetic resonance imaging systems, Food and Drug Administration, 1997. Available at: <http://www.fda.gov/cdrh/ode/primerf6.html>. Accessed June 13, 2004.
 11. Faulkner W. *MRI: Basic Physics, Instrumentation, and Quality Control*. Malden, Mass: Blackwell Science; 2002.
 12. Berger A. Magnetic resonance imaging. *BMJ*. 2002;324:35.
 13. Schenck JF. Safety of strong, static magnetic fields. *J Magn Reson Imaging*. 2000;12:2–19.
 14. ECRI. Hazard report: patient death illustrates the importance of adhering to safety precautions in magnetic resonance environments. Available at: http://www.ecri.org/document/hazard_MRI080601.pdf. Accessed January 6, 2004.
 15. Dempsey MF, Condon B, Hadley DM. MRI safety review. *Semin Ultrasound CT MRI*. 2002;23:392–401.
 16. Kanal E, Borgstede JP, Barkovich AJ, Bell C, Bradley WG, et al. ACR Blue Ribbon Panel Response to the AJR Commentary by Drs. Crues and Shellock on the ACR White Paper on Magnetic Resonance (MR) Safety. Available at: http://www.acr.org/committees/mr_safety/mr_response.html. Accessed January 28, 2004.
 17. Shellock FG. *Reference Manual for Magnetic Resonance Safety, Implants & Devices*. Los Angeles, Calif: Biomedical Research Publishing Group; 2004.
 18. Shellock FG. Magnetic resonance safety update 2002: implants and devices. *J Magn Reson Imaging*. 2002; 16:485–496.
 19. Shellock FG, Crues JV III. MR safety and the American College of Radiology White Paper. *AJR Am J Roentgenol*. 2002;178:1349–1352.
 20. Bell C. Anesthesia in the MR suite. Available at: <http://www.gasnet.org/mri/introduction.php>. Accessed June 15, 2004.
 21. Pennock JM. Patient preparation, safety and hazards in imaging infants and children. In: Rutherford MA, ed. *MRI of the Neonatal Brain*. London, England: WB Saunders; 2002:3–15.
 22. Center for Devices and Radiological Health. Guidance for industry and FDA staff. Criteria for significant risk investigations of magnetic resonance diagnostic devices. U.S. Food and Drug Administration, 2003. Available at: <http://www.fda.gov/cdrh/ode/guidance/793.pdf>. Accessed January 5, 2004.
 23. Dempsey MF, Condon B. Thermal injuries associated with MRI: a review. *Clin Radiol*. 2001;56:457–465.
 24. Maalouf EF, Counsell SJ. Imaging the preterm infant: practical issues. In: Rutherford MA, ed. *MRI of the Neonatal Brain*. London, England: WB Saunders; 2002:17–21.
 25. Groenendaal F, Leusink C, Nijenhuis M, Janssen MJ. Neonatal life support during magnetic resonance imaging. *J Med Engin Technol*. 2002;26:71–74.
 26. Schaefer DJ, Bourland JD, Nyenhuis JA. Review of patient safety in time-varying gradient fields. *J Magn Reson Imaging*. 2000;12:20–29.
 27. McJury M, Shellock FG. Auditory noise associated with MR procedures: a review. *J Magn Reson Imaging*. 2000;12:37–45.
 28. Battin M, Maalouf EF, Counsell S, Herlihy A, Hall A, et al. Physiologic stability of preterm infants during magnetic resonance imaging. *Early Hum Dev*. 1998;52:101–110.
 29. Taber KH, Hayman LA, Northrup SR, Maturi L. Vital sign changes during infant magnetic resonance examinations. *J Magn Reson Imaging*. 1998;8:1252–1256.
 30. Philbin MK, Taber KH, Hayman LA. Preliminary report: changes in vital signs of term newborns during MR. *Am J Neuroradiol*. 1996;17:1033–1036.
 31. Miettinen S. Safety precautions in MRI environments. Available at: http://www.datex-ohmeda.com/clinical/cw_prev_10_article4.htm#. Accessed June 15, 2004.
 32. Barkovich JA. Techniques and methods in pediatric neuroimaging. In: Barkovich AJ, ed. *Pediatric Neuroimaging*. 3rd ed. Philadelphia, Pa: Lippincott, Williams & Wilkins; 2000:4–18.
 33. University of California San Francisco Department of Radiology. Images Available at: <http://www.ucsfhealth.org/adult/pubs/images/images2001.pdf>. Accessed January 5, 2004.
 34. Kanal E, Borgstede JP, Barkovich AJ, Bell C, Bradley WG, et al. American College of Radiology White Paper on MR safety: 2004 update and revisions. *AJR Am J Roentgenol*. 2004;182:1111–1114.
 35. Walden M, Carrier CT. Sleeping beauties: the impact of sedation on neonatal development. *J Obstet Gynecol Neonatal Nurs*. 2003;32:393–401.
 36. Malviya S, Voepel-Lewis T, Tait AR, Merkel S. Sedation/analgesia for diagnostic and therapeutic procedures in children. *J PeriAnesth Nurs*. 2000;15:415–422.
 37. Ng E, Taddio A, Ohlsson A. Intravenous midazolam infusion for sedation of infants in the neonatal intensive care unit. *Cochrane Database Syst Rev*. 2003;CD002052.
 38. American Academy of Pediatrics. Committee on Drugs. Guidelines for monitoring and management of pediatric patients during and after sedation for diagnostic and therapeutic procedures: addendum. *Pediatrics*. 2002; 110:836–838.
 39. Hummell PA, Puchalski ML, Creech SD, Weiss MC. Neonatal pain, agitation and sedation scale—reliability and validity. Abstract presented at the Pediatric Academic Society Meeting. Seattle, Washington, May 6, 2003.
 40. Colletti PM. Size “H” oxygen cylinder: accidental MR projectile at 1.5 Tesla. *J Magn Reson Imaging*. 2004;19:141–143.
 41. Vigneron DB, Barkovich AJ, Noworolski SM, von dem Bussche M, Henry RG, et al. Three-dimensional proton MR spectroscopic imaging of premature and term neonates. *Am J Neuroradiol*. 2001;22:1424–1433.
 42. UCSF Children’s Hospital. Magnetic resonance (MR) compatible neonatal transport incubator. Available at: www.ucsfhealth.org/childrens/innovations/2003_q2/clinic/9.html. Accessed January 6, 2004.
 43. Huppi PS, Warfield S, Kikinis R, Barnes P, Zientara GP, et al. Quantitative magnetic resonance imaging of brain development in premature and term newborns. *Ann Neurol*. 1998;43:224–235.

44. Whitby EH, Griffiths PD, Lonnecker-Lammers T, Srinivasan R, Connolly DJ, et al. Ultrafast magnetic resonance imaging of the neonate in a magnetic resonance compatible incubator with built-in coil. *Pediatrics*. 2004;113:e150–e152.
 45. Dumoulin CL, Rohling KW, Piel JE, Rossi CJ, Giaquinto RO, et al. Magnetic resonance imaging compatible neonate incubator. *Magn Res Engineering*. 2002;15:117–128.
 46. Erberich SG, Friedlich P, Seri I, Nelson MD, Bluml S. Functional MRI in neonates using neonatal head coil and MR compatible incubator. *Neuroimage*. 2003;20:683–692.
 47. Srinivasan R, Loenneker-Lammers T, Shah R. MR compatible incubator for imaging pre- and term neonates. *Proc Intl Mag Reson Med*. 2002;10:799.
 48. Bluml S, Friedlich P, Erberich S, Wood JC, Seri I, et al. MR imaging of newborns by using an MR-compatible incubator with integrated radiofrequency coils: initial experience. *Radiology*. 2004;231:594–601.
 49. Blaicher W, Bernaschek G, Deutinger J, Messerschmidt A, Schindler E, et al. Fetal and early postnatal magnetic resonance imaging—is there a difference? *J Perinat Med*. 2004;32:53–57.
-

See page 52 for CE test questions.